

Cardiac lymphoma and pericardial effusion in dogs: 12 cases (1994–2004)

John M. MacGregor, DVM; Maria L. E. Faria, DVM, PhD; Antony S. Moore, MVSc, DACVIM;
Anthony H. Tobias, BVSc, PhD, DACVIM; Donald J. Brown, VMD, PhD, DACVIM;
Helio S. A. de Morais, DVM, PhD, DACVIM

Objective—To determine clinical characteristics and clinicopathologic findings, including results of pericardial fluid analysis, and determine the outcome associated with pericardial effusion caused by cardiac lymphoma in dogs.

Design—Retrospective case series.

Animals—12 dogs.

Procedure—Medical records of affected dogs were reviewed for echocardiographic findings, radiographic findings, results of pericardial fluid analysis, clinicopathologic findings, treatment protocols, and outcomes.

Results—Pericardial effusion was detected by echocardiography in all 12 dogs, and lymphoma was detected by cytologic examination of the effusion (11/12 dogs) or histologic examination of pericardium (3/12). Large-breed dogs were overrepresented; median weight was 40.5 kg (89.1 lb). Most hematologic and biochemical changes were mild and non-specific. Survival time for dogs treated with combination chemotherapeutic agents was 157 days and for dogs that did not receive chemotherapy survival time was 22 days. This difference was not significant, but several dogs had long-term survival.

Conclusions and Clinical Relevance—Cardiac lymphoma is an uncommon cause of pericardial effusion, and results suggest that cardiac lymphoma does not always warrant the poor prognosis of other stage V, substage b lymphomas. (*J Am Vet Med Assoc* 2005; 227:1449–1453)

Rapid accumulation of pericardial effusion that causes cardiac tamponade results in signs of acute forward heart failure or cardiogenic shock (eg, weakness, collapse, hypothermia, or pallor), whereas slower accumulation leads predominantly to signs of right-sided con-

gestive heart failure (eg, ascites, distended jugular veins, hepatomegaly, or pleural effusion). Historically, pericardial fluid analysis and cytologic examination have failed to identify the cause of pericardial effusion in most dogs.^{1,2} Pericardial fluid from dogs with idiopathic or neoplastic pericardial effusion usually has a grossly sanguinous or “port wine” appearance, and most myocardial tumors associated with pericardial effusion do not exfoliate well. Neoplastic cells from dogs with pericardial mesothelioma exfoliate abundantly, but it is difficult to differentiate between reactive and neoplastic mesothelial cells via cytologic examination.^{3,5} The pH⁶ and cardiac troponin I concentrations⁴ in the fluid have been used to distinguish neoplastic from nonneoplastic effusions. Initially, pH was thought to be useful, but subsequent studies^{7,b} have called this finding into question.

The 3 most common neoplastic causes of pericardial effusion in dogs are myocardial hemangiosarcoma, chemodectoma, and mesothelioma. Pericardial effusion caused by lymphoma is rare in dogs, occurring in only 2 of the 164 (1.2%) cases summarized in 3 previous studies^{1,2,8} in this species. Prognosis for dogs with pericardial effusion varies depending on the cause of the effusion. Dogs with idiopathic effusion and effusion caused by intrapericardial chemodectomas have a median survival time much longer than 1 year,^{9,12} whereas dogs with pericardial effusion attributable to myocardial hemangiosarcoma have historically had a median survival time of < 3 weeks.^{13,14} A recent study¹⁵ found that surgical resection of right atrial hemangiosarcoma prolongs median survival time to 56 days with 13% perioperative death and adjuvant chemotherapy increases survival time to 156 days. The clinical course and survival times for dogs with pericardial effusion caused by cardiac lymphoma have not been reported to our knowledge.

Primary cardiac lymphoma is defined as lymphoma involving the heart, pericardium, or both.¹⁶ In dogs, the heart is rarely affected by lymphoma; prevalence is low in postmortem studies^{17,19} and in searches for cardiac neoplasia in the Veterinary Medical Database at Purdue University.²⁰ Prognosis for canine lymphoma is affected by its location and whether or not the dog has clinical signs related to the neoplasia. Lymphoma is most frequently classified by use of the World Health Organization stage (extent of disease) and substage (whether or not clinical signs are detected). By these criteria, cardiac lymphoma with pericardial effusion is classified as stage V (extranodal in an organ other than the liver or spleen), substage b (with clinical signs). Dogs with stage III lymphoma or higher and clinical signs (substage b) have a substantially

From the Department of Clinical Sciences, School of Veterinary Medicine, Tufts University, North Grafton, MA 01536 (MacGregor, Moore, Brown); the Department of Veterinary Clinical Sciences, Universidade Estadual de Londrina, Brazil (Faria, de Morais) 86051-990; and the Department of Veterinary Clinical Sciences, College of Veterinary Medicine, University of Minnesota, Saint Paul, MN 55108 (Tobias). Dr. Faria's present address is Department of Surgical Sciences, School of Veterinary Medicine, University of Wisconsin, Madison, WI 53706. Dr. de Morais' present address is Department of Medical Sciences, School of Veterinary Medicine, University of Wisconsin, Madison, WI 53706. Dr. Moore's present address is Veterinary Oncology Consultants, 379 Lake Innes Dr, Wauchope, NSW 2446 Australia. Dr. MacGregor's present address is Dover Veterinary Hospital, 96 Durham Rd, Dover, NH 03820.

Address correspondence to Dr. MacGregor.

worse prognosis for remission and survival than those with lower-stage lymphoma.²¹⁻²⁶ Thus, cardiac lymphoma is among the categories that historically have the worst prognosis.

Cardiac lymphoma is a rare, but potentially treatable, cause of pericardial effusion in dogs. There are few descriptions of antemortem diagnosis of pericardial lymphoma in dogs,²⁷⁻²⁹ and there have been no studies detailing clinical findings and prognosis in dogs with cardiac lymphoma. Consequently, the purpose of the study reported here was to describe historical and clinical findings, treatment protocols, and survival in dogs with pericardial effusion caused by cardiac lymphoma.

Criteria for Selection of Cases

Medical records from all dogs examined by the Cardiology Service of the Foster Hospital for Small Animals at the School of Veterinary Medicine, Tufts University (TU); the Thoracic Medicine Service of the Hospital Veterinário, Universidade Estadual de Londrina (UEL), Brazil, from 1994 to 2002; and the Cardiology Service at the College of Veterinary Medicine, University of Minnesota (UM), from January 2000 to November 2004 were reviewed. Dogs were included if pericardial effusion was diagnosed by use of echocardiography and either a cytologic diagnosis of lymphoma from pericardial fluid analysis or a histopathologic diagnosis from a pericardial biopsy specimen. All cytologic and histopathologic diagnoses were made by board-certified clinical pathologists or anatomic pathologists.

Procedure

Data collected from the medical records included history, signalment (age, breed, and sex) at the time of diagnosis, initial owner complaints, and physical examination findings. Additionally, radiographic, electrocardiographic, and echocardiographic abnormalities; clinical pathology data including CBC and serum biochemical analyses; and pericardial fluid analysis were compiled. Diagnoses made by use of either histologic examination of pericardial biopsy specimens, cytologic examination of pericardial fluid, or both were noted. Treatment (when attempted) and outcome were determined. Dogs were defined as being treated if they received at least 1 treatment of a standard multidrug chemotherapy protocol; dogs that received prednisone alone were defined as not treated. Length of survival was calculated from the time of cytologic or histopathologic diagnosis. When complete outcome data were not available in the records, telephone interviews were conducted with clients and referring veterinarians until all outcomes and treatments were identified. No dogs were lost to follow-up.

Statistical analyses—Dogs reached the end point when they died regardless of the cause of death. Dogs that were still alive at last contact were censored. Kaplan-Meier survival curves were performed to assess the association of potential prognostic factors with survival time. Factors included age, sex, weight, duration of signs, serum **alanine aminotransferase (ALT)** activ-

ity, and treatment with chemotherapy other than prednisone. Cox logistic regression was performed to determine significance. Statistical curves were compared by use of the log-rank test. For all comparisons, $P < 0.05$ was considered significant.

Results

A total of 7,248 records (3,440 from TU, 1,530 from UEL, and 2,278 from UM) were examined, and 12 dogs (6 at TU, 4 at UEL, and 2 at UM) met the initial inclusion criteria. A description of one of the dogs included in this case series has been published.²⁷

The prevalence rate of cardiac lymphoma among the participating Cardiology and Thoracic Medicine Services was 0.17% (ratio, 1/604 dogs). Age ranged from 2 to 16 years (median, 8 years), and 8 dogs were male (5 neutered) and 4 were female (2 spayed). All purebred dogs were large breeds and included 4 Labrador Retrievers, 2 Golden Retrievers, 2 Rottweilers, 1 Fila Brasileiro, and 1 American Bulldog. There were also 2 mixed-breed dogs that weighed 9.0 and 31.0 kg (19.8 and 68.2 lb), respectively. Weights of all 12 dogs ranged from 9.0 to 61.0 kg (19.8 to 134.2 lb) with a median of 40.5 kg (89.1 lb).

Clinical signs in 11 of 12 dogs were evident for 1 to 7 days (median, 3 days) prior to diagnosis of primary cardiac lymphoma. The remaining dog had intermittent signs related to pericardial effusion during the preceding 7 months, and pericardiocentesis had been performed twice by the referring veterinarian. Historical clinical signs that were evident in more than 1 dog included lethargy ($n = 8$), dyspnea or panting (8), abdominal distention (8), partial or complete anorexia (5), vomiting (3), cough (2), and polydypsia (2). Physical examination abnormalities were most commonly related to right-sided congestive heart failure ($n = 5$), forward heart failure (3), or both (3). An arrhythmia was detected during physical examination of 1 dog that was evaluated for mild and vague acute-onset clinical signs. This finding led to detection of pericardial effusion via echocardiography. Of the signs associated with right-sided heart failure, ascites was most common ($n = 8$). Weakness or collapse was the most common sign of forward heart failure ($n = 6$). Clinical findings at initial examination attributed to pericardial effusion included weak pulses ($n = 8$), muffled heart sounds (7), and pulsus paradoxus (3).

Complete blood counts and serum biochemical profiles were performed in all dogs. Hematologic and serum biochemical abnormalities, when detected, were mild and nonspecific. Mild anemia (Hct range, 26% to 37%; reference range, 39% to 55%) was detected in 4 dogs, and elements of a stress leukogram (lymphopenia, mature neutrophilia, or both) were detected in 4 dogs. Low serum albumin concentration, low total protein concentration, or both were detected in 4 dogs, whereas 5 dogs had high serum total protein concentration. Eight dogs had high serum activity of ALT, aspartate aminotransferase, or both. Additionally, mild serum hyperphosphatemia was detected in 2 dogs, mild hyperkalemia was detected in 2 dogs, and mild hypercalcemia was detected in 1 dog. Serum *Ehrlichia canis* antibody titers were measured in 2 dogs. Both

had high titers, but a polymerase chain reaction assay for *Ehrlichia* spp failed to confirm infection in 1 dog and was not performed in the other. No other hematologic or serum biochemical abnormalities were detected in more than 1 dog. Bone marrow aspirates performed in 2 dogs yielded unremarkable results in 1 dog and revealed mild erythroid hypoplasia in the other. A third dog had no evidence of bone marrow neoplasia on postmortem examination. Analysis of ascites revealed lymphoma in the abdomen in 1 dog.

Electrocardiograms were recorded in 6 dogs. Three dogs had small QRS complexes (< 1 mV in lead II), 1 had mild electrical alternans, and 1 had a normal sinus rhythm interspersed with periods of accelerated idioventricular rhythm and occasional premature ventricular complexes. While being monitored, the latter dog developed complete atrioventricular block for 10 minutes, which abruptly degenerated to terminal ventricular fibrillation.

Abdominal radiography performed in 2 dogs revealed decreased abdominal detail because of ascites. Radiographic and echocardiographic abnormalities were typical for dogs with pericardial effusion. Pleural effusion was detected in 1 dog, whereas 11 dogs had enlarged and globoid cardiac silhouettes on thoracic radiographs. Marked pericardial effusion with phasic right atrial and ventricular collapse was detected via echocardiography in 9 dogs. Three dogs had only mild to moderate pericardial effusion. No intrapericardial masses were identified in any dogs.

Cardiac lymphoma was diagnosed solely via cytologic examination of the pericardial fluid in 8 of 12 dogs. In 1 dog, the diagnosis was made via histologic examination of the pericardium, which was obtained at pericardiectomy. In 3 dogs, both cytologic and histopathologic diagnoses of lymphoma were made. Necropsy was performed in 1 dog, and lymphoma was found exclusively in the heart and pericardium. In 2 dogs, immunohistochemical stains were applied to histologic sections and revealed combinations of cell-surface markers that were most consistent with T-cell lymphoma. One dog had positive results for CD3 antigen, a T-cell marker, and negative results for HM57 antigen, a B-cell marker. The other dog had positive results for CD3 antigen and negative results for CD79, a B-cell marker, but had some scattered staining for CD20, a B-cell marker. In 1 dog, immunohistochemical stains were applied to cytologic preparations of the pericardial fluid. The lymphoblasts in that dog yielded negative results for CD3 antigen, positive results for CD79, and variably positive results for CD21 (a B-cell marker), which yielded a diagnosis of B-cell lymphoma.

Biochemical analysis of the pericardial fluid was performed in 11 dogs. Color of the fluid was red in 8 of 9 dogs for which a gross appearance was noted. The PCV ranged from 2% to 17% (median, 8%) in these 8 dogs. In 1 dog, the fluid was yellow and slightly flocculent. Total protein concentration (n = 11 dogs) of the fluid ranged from 3.2 to 6.6 g/dL (median, 4.2 g/dL). Nucleated cell counts (n = 10 dogs) ranged from 29.4 to 64.9 × 10³ cells/μL (median, 37.1 × 10³ cells/μL) in dogs for which it was reported. Pericardial fluid pH measured in 1 dog was 7.26.

Median survival time among all 12 dogs was 41 days (95% confidence interval, 20 to 124 days; **Figure 1**). Of the 7 dogs that did not receive combination chemotherapy, 2 dogs received no additional therapy after pericardiocentesis and 2 were palliatively treated with furosemide after pericardiocentesis. The 2 untreated dogs died 7 and 15 days after diagnosis, respectively. Of the dogs that received furosemide, 1 was also administered antimicrobials by the referring veterinarian and was euthanatized 7 days after diagnosis and the other died at home 52 days after diagnosis. In the remaining 3 dogs, 1 had 3 treatments via pericardiocentesis and died of gastric torsion 124 days after diagnosis. One dog received prednisone after the initial pericardiocentesis and was euthanatized 22 days later because of recurrent and progressive signs. One dog was treated with a single pericardiocentesis followed by partial pericardiectomy and received no other treatment. This dog was alive without clinical signs of pericardial effusion 1,169 days after diagnosis. Median survival time for the 7 dogs that received no combination antineoplastic chemotherapy was 22 days (95% confidence interval, 7 to 52 days).

Five dogs were treated with combination antineoplastic chemotherapy either after the initial therapeutic pericardiocentesis alone (n = 4) or after pericardiocentesis followed by partial pericardiectomy (2). Dogs received various combinations of prednisone (n = 5), vincristine (5), cyclophosphamide (4), L-asparaginase (4), doxorubicin (4), mechlorethamine (1), procarbazine (1), lomustine (1), and adjunctive radiation therapy (1). Median survival time of 5 dogs that received combination chemotherapy was 157 days (95% confidence interval, 20 to > 157 days), which was not significantly different from those that received no chemotherapy (P = 0.259). If the dog that survived > 1,169 days was excluded from analysis, median survival time for the remaining 6 dogs that did not receive combination chemotherapy was 15 days (95% confidence interval, 7 to 22 days) and a survival benefit ascribable to combination chemotherapy became significant (P = 0.047; **Figure 2**).

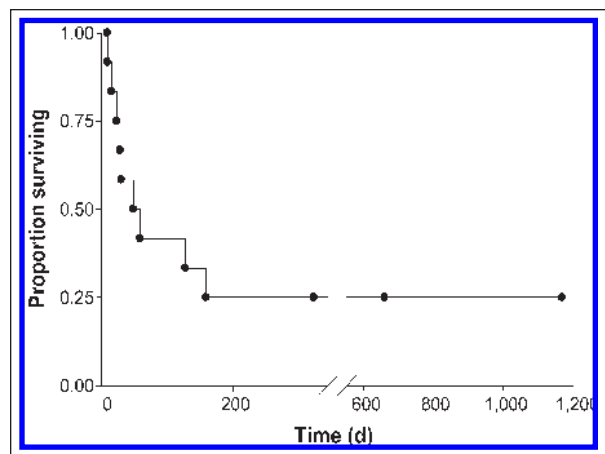


Figure 1—Kaplan-Meier survival curve for 12 dogs with primary cardiac lymphoma and pericardial effusion. • = Death of dog or last contact. No dogs were censored. Three dogs were still alive at last contact at 328, 659, and 1,169 days, respectively.

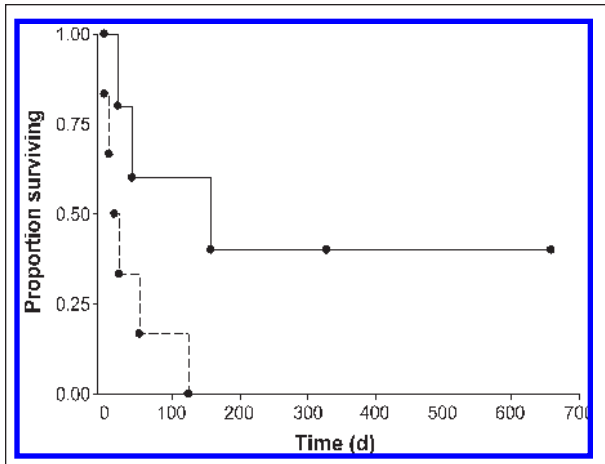


Figure 2—Kaplan-Meier survival curve for 12 dogs with primary cardiac lymphoma and pericardial effusion that did not receive chemotherapy (dashed line) or did receive chemotherapy (solid line). Two dogs were censored (alive at last contact at 328 and 659 days, respectively). One dog (outlier) was excluded from the nontreated group. See Figure 1 for key.

Kaplan-Meier survival curves of potential prognostic factors, including, sex ($P = 0.97$), weight ($P = 0.79$), duration of signs ($P = 0.79$), serum ALT activity ($P = 0.68$), and treatment with chemotherapy other than prednisone, were not found to be significant except as noted.

Discussion

Primary cardiac lymphoma in humans is a non-Hodgkin's lymphoma involving primarily the heart or pericardium.³⁰ In this study, we identified 12 dogs with pericardial effusion caused by cardiac lymphoma. The designation of primary cardiac lymphoma could not be made definitively in this cohort of dogs because necropsy was performed in only 1 dog. There still exists the possibility that despite having clinical signs mainly referable to cardiac lymphoma, these dogs could have had multicentric lymphoma similar to a case previously described.²⁹ However, because there were no other physical examination or imaging findings that suggested lymphoma in other organs, it is likely that at least some of these dogs did have primary cardiac lymphoma. Median survival time among the 12 dogs was 41 days. Median survival time for dogs that received combination chemotherapy was 157 days versus 22 days for dogs that did not receive combination chemotherapy. Three of 12 dogs were alive ≥ 328 days after the diagnosis. This prolonged period of survival in some dogs with primary cardiac lymphoma is surprising given the poor prognosis of the most common malignant myocardial neoplasm, hemangiosarcoma,¹³⁻¹⁵ and the relatively poor prognosis for dogs with stage V, substage b lymphoma.^{22,31,32}

Clinical findings among the dogs in this study were fairly uniform but not particularly specific. Dogs were generally of large breeds, and only 1 dog weighed < 25 kg, which was similar to the population at risk for idiopathic and other neoplastic forms of pericardial effusion. Clinical signs were detected for a median of 3 days prior to evaluation. Most dogs had signs consistent with right-sided or low-output heart failure,

including ascites, weak pulses, jugular venous distention, and pulsus paradoxus. These clinical signs are common with cardiac tamponade irrespective of cause and are not specific for cardiac lymphoma.

Prognosis for dogs with pericardial effusion caused by neoplasia varies widely on the basis of the type of neoplasia detected. Median survival time for dogs with cardiac lymphoma has not been reported.²⁷ However, myocardial lymphoma has been reported in 3 related Otterhounds, 1 of which survived for more than a year while receiving prednisolone alone.³³

Lymphoma is a disease that frequently responds well to chemotherapy. Combination protocols that include doxorubicin have consistently been associated with the longest disease-free intervals in treatment for lymphoma in veterinary patients^{22,24,34,35} and human patients.³⁶ A cat with presumptive infiltrative cardiac lymphoma was treated with chemotherapy consisting of prednisone, cyclophosphamide, and vincristine. This regimen resulted in clinical improvement. Unfortunately, cytologic and histologic confirmation of the presumptive diagnosis was not made, although lymphoma was confirmed elsewhere in the cat.³⁷ One of the dogs in the group reported here did not receive any chemotherapy and was alive 1,169 days after diagnosis. This dog had no recurrence of clinical signs related to lymphoma despite being treated only via pericardectomy. The length of survival was remarkable given the malignant and aggressive nature of stage V, substage b lymphoma. One explanation is that surgery was curative, although that is unlikely given the systemic nature of lymphoma; an alternative explanation is that the dog had spontaneous remission of the lymphoma. In our opinion, excluding this outlier gives a more realistic expectation of the survival benefit of combination chemotherapy. All other dogs that did not receive combination chemotherapy were dead by 124 days after diagnosis.

Primary cardiac lymphoma in immunocompetent humans has similarities to the findings of the dogs in this study, as it is a rare condition. It is, however, increasing in frequency in humans with acquired immunodeficiency disease.^{38,39} Prior to 1991, only 21 cases had been diagnosed in the human literature, 5 of which were diagnosed antemortem and 2 of which resulted in treatment with chemotherapy or radiation.⁴⁰ B-cell lymphoma comprises 80% of such tumors, and chemotherapy was used in 31 of 66 patients with a median survival time of 7 months (range, 0 to 48 months).¹⁶ Similar to dogs in this study, in human patients in which clinical pathology data have been obtained, nonspecific increases in serum liver enzyme activities have been detected along with nonspecific hematologic changes. An additional similarity to the cases reported here is that despite availability of more sophisticated means of testing in human patients, most primary cardiac lymphomas are diagnosed via cytologic examination of pericardial fluid alone.^{40,41}

Pericardial effusion caused by cardiac lymphoma results in clinical signs that are nonspecific, and effusion caused by cardiac lymphoma is not usually grossly different from effusion attributable to other causes. Further research is needed to establish with complete

certainty whether combination chemotherapy provides a clinically important benefit in dogs with cardiac lymphoma. However, it is important to note that combined chemotherapy did provide a significant survival benefit when the unusual long-term survivor was excluded from analysis.

- a. Linde A, Summerfield NJ, Clifford CA, et al. Cardiac troponin I levels in pericardial effusion and peripheral blood from dogs with neoplastic versus non-neoplastic etiologies (abstr). *J Vet Intern Med* 2003;17:441.
- b. de Laforcade AM, Rozanski ER, Freeman LM, et al. Biochemical analysis of pericardial fluid and whole blood in 23 dogs (abstr). *J Vet Emerg Crit Care* 2000;10:206.

References

1. Berg RJ, Wingfield W. Pericardial effusion in the dog: a review of 42 cases. *J Am Anim Hosp Assoc* 1984;20:721–730.
2. Sisson D, Thomas WP, Ruehl WW, et al. Diagnostic value of pericardial fluid analysis in the dog. *J Am Vet Med Assoc* 1984;184:51–55.
3. Peters M, Tenhundfeld J, Stephan I, et al. Embolized mesothelial cells within mediastinal lymph nodes of three dogs with idiopathic haemorrhagic pericardial effusion. *J Comp Pathol* 2003;128:107–112.
4. McDonough SP, MacLachlan NJ, Tobias AH. Canine pericardial mesothelioma. *Vet Pathol* 1992;29:256–260.
5. Churg A, Colby TV, Cagle P, et al. The separation of benign and malignant mesothelial proliferations. *Am J Surg Pathol* 2000;24:1183–1200.
6. Edwards NJ. The diagnostic value of pericardial fluid pH determination. *J Am Anim Hosp Assoc* 1996;32:63–67.
7. Fine DM, Tobias AH, Jacobs KA. Use of pericardial fluid pH to distinguish between idiopathic and neoplastic effusions. *J Vet Intern Med* 2003;17:525–529.
8. Dunning D, Monnet E, Orton EC, et al. Analysis of prognostic indicators for dogs with pericardial effusion: 46 cases (1985–1996). *J Am Vet Med Assoc* 1998;212:1276–1280.
9. Kerstetter KK, Krahwinkel DJ Jr, Millis DL, et al. Pericardiectomy in dogs: 22 cases (1978–1994). *J Am Vet Med Assoc* 1997;211:736–740.
10. Erhart N, Erhart EJ, Willis J, et al. Analysis of factors affecting survival of dogs with aortic body tumors. *Vet Surg* 2002;31:44–48.
11. Bouvy BM, Bjorling DE. Pericardial effusion in dogs and cats. Part I. Normal pericardium and causes and pathophysiology of pericardial effusion. *Compend Contin Educ Pract Vet* 1991;13:417–424.
12. Vicari ED, Brown DC, Holt DE, et al. Survival times of and prognostic indicators for dogs with heart base masses: 25 cases (1986–1999). *J Am Vet Med Assoc* 2001;219:485–487.
13. Aronson M. Cardiac hemangiosarcoma in the dog: a review of 38 cases. *J Am Vet Med Assoc* 1985;187:326–337.
14. Ogilvie GK, Moore AS. Hemangiosarcoma. In: Ogilvie GK, Moore AS, eds. *Managing the veterinary cancer patient: a practice manual*. Trenton, NJ: Veterinary Learning Systems, 1995;367–373.
15. Weisse C, Soares N, Beal MW, et al. Survival times in dogs with right atrial hemangiosarcoma treated by means of surgical resection with or without adjuvant chemotherapy: 23 cases (1986–2000). *J Am Vet Med Assoc* 2005;226:575–579.
16. Rolla G, Bertero MT, Pastena G, et al. Primary lymphoma of the heart: a case report and review of the literature. *Leukemia Res* 2002;26:117–120.
17. Cobb MA, Brownlie SE. Intrapericardial neoplasia in 14 dogs. *J Small Anim Pract* 1992;33:309–316.
18. Girard C, Helie P, Odin M. Intrapericardial neoplasia in dogs. *J Vet Diagn Invest* 1999;11:73–78.
19. Walter JH, Rudolph R. Systemic metastatic, eu- and hetero-
- tope tumours of the heart in necropsied dogs. *Zentralbl Veterinarmed [A]* 1996;43:31–45.
20. Ware WA, Hopper DL. Cardiac tumors in dogs: 1982–1995. *J Vet Intern Med* 1999;13:95–103.
21. Teske E, van Heerde P, Rutteman GR, et al. Prognostic factors for treatment of malignant lymphoma in dogs. *J Am Vet Med Assoc* 1994;205:1722–1728.
22. Keller ET, MacEwen EG, Rosenthal RC, et al. Evaluation of prognostic factors and sequential combination chemotherapy with doxorubicin for canine lymphoma. *J Vet Intern Med* 1993;7:289–295.
23. Hahn KA, Richardson RC, Hahn EA, et al. Diagnostic and prognostic importance of chromosomal aberrations identified in 61 dogs with lymphosarcoma. *Vet Pathol* 1994;31:528–540.
24. Myers NC, Moore AS, Rand WM, et al. Evaluation of a multidrug chemotherapy protocol (ACOPA II) in dogs with lymphoma. *J Vet Intern Med* 1997;11:333–339.
25. Baskin C, Couto CG, Wittum TE. Factors influencing first remission and survival in 145 dogs with lymphoma: a retrospective study. *J Am Anim Hosp Assoc* 2000;36:404–409.
26. Ruslander DA, Gebhard DH, Tompkins MB, et al. Immunophenotypic characterization of canine lymphoproliferative disorders. *In Vivo* 1997;11:169–172.
27. Sims CS, Tobias AH, Hayden DW, et al. Pericardial effusion due to primary cardiac lymphosarcoma in a dog. *J Vet Intern Med* 2003;17:923–927.
28. Pereira PM, Camacho AA, Selmi AL, et al. Cardiac lymphoma in dogs: a report of two cases. *Ars Veterinaria* 1997;13:192–197.
29. Ogilvie GK, Brunkow CS, Daniel GB, et al. Malignant lymphoma with cardiac and bone involvement in a dog. *J Am Vet Med Assoc* 1989;194:793–796.
30. McAllister HJ, Fenoglio JJ. Tumors of the cardiovascular system. In: *Atlas of tumor pathology. 2nd series, fascicle 15*. Washington, DC: Armed Forces Institute of Pathology, 1978;99–100.
31. MacEwan EG, Hayes AA, Brown NO, et al. Cyclic combination chemotherapy of canine lymphosarcoma. *J Am Vet Med Assoc* 1981;178:1178–1181.
32. MacEwan EG, Hayes AA, Brown NO, et al. Evaluation of some prognostic factors for advanced multicentric lymphosarcoma in the dog: 147 cases (1978–1981). *J Am Vet Med Assoc* 1987;190:564–568.
33. Teske E, de Vos JP, Egberink HF, et al. Clustering in canine malignant lymphoma. *Vet Q* 1994;16:134–136.
34. Moore AS, Cotter SM, Rand WM, et al. Evaluation of a discontinuous treatment protocol (VELCAP-S) for canine lymphoma. *J Vet Intern Med* 2001;15:348–354.
35. Garrett LD, Thamm DH, Chun R, et al. Evaluation of a 6-month chemotherapy protocol with no maintenance therapy for dogs with lymphoma. *J Vet Intern Med* 2002;17:704–709.
36. Freedman AS, Nadler LM. Non-Hodgkin's lymphomas. In: Holland JF, Morton DL, Bast RC, et al, eds. *Cancer medicine*. Philadelphia: The Williams & Wilkins Co, 1997;2757–2796.
37. Brummer DG, Moise NS. Infiltrative cardiomyopathy responsive to combination chemotherapy in a cat with lymphoma. *J Am Vet Med Assoc* 1989;195:1116–1119.
38. Aboulafia DM, Bush R, Picozzi VJ. Cardiac tamponade due to primary pericardial lymphoma in a patient with AIDS. *Chest* 1994;106:1295–1299.
39. Ceresoli GL, Ferreri AJ, Bucci E, et al. Primary cardiac lymphoma in immunocompetent patients: diagnostic and therapeutic management. *Cancer* 1997;80:1497–1506.
40. Roller MB, Manoharan A, Lyoff R. Primary cardiac lymphoma. *Acta Hematol* 1991;85:47–48.
41. Chao TY, Han S, Nieh S, et al. Diagnosis of primary cardiac lymphoma: report of a case with cytologic examination of pericardial fluid and imprints of transvenously biopsied intracardiac tissue. *Acta Cytol* 1995;39:955–959.